



31 January 2025

John L. Alonge, MS, DDS

*I attest that I have no conflicts of interest and have no financial interest or compensation with any dental, medical or pharmaceutical company.

Minimally Invasive Exodontia

John L. Alonge, M.S., D.D.S.

jladoc@aol.com




Clinical Desires of GP's

- Techniques
- Time
- Trouble



Keys to Success

- Diagnosis/Work-up
- Anxiety & Pain Control
- Techniques
- Problems



Keys to Success

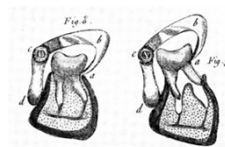
- Treatment Room Preparation
- Doctor-Staff Communication
- Patient Positioning
- Doctor-Staff Positioning
- Confidence



Dentoalveolar Surgery

Armamentarium & Techniques


- Pelican
- Key



Dentoalveolar Surgery

Miscellaneous Armamentarium

- *Silicone bite blocks
- *Elevators (Root, "East-West")
- *Rongeurs (Blumenthal)
- *Curette
- *Bone file
- *Upper root forceps
- *Lower root forceps
- *Molar Forceps



"It's coming."

Local Anesthesia

"There is no substitute for profound local anesthesia".



"Nurse, run outside and get his shoe."

Dentoalveolar Surgery

Basic Armamentarium

- *Periosteal elevator
 - Molt #9
 - Hourigan PH 2

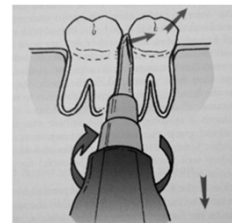


Dentoalveolar Surgery

Basic Armamentarium

*Elevator

- 301
- 34S
- E303
- 77R
- 92R



Dentoalveolar Surgery

Basic Armamentarium

- *Forceps
 - Upper "universal"
 - Lower "universal"
 - #23 "cowhorn"
 - Ash



"If you've got any screaming to do, wait until you get off the premises."

Dentoalveolar Surgery

"Atraumatic Extraction"

- Periostome
- Luxator
 - X-Otomes™
 - Proximators™
 - PDL-Evators™
 - Zators™
- Piezotome™
- Powertome™



Principles of Exodontia

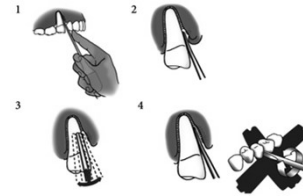
- *Access
- *Pathway of Removal
- *Controlled Force



"I'll have to charge extra for that one."

Minimally Invasive Exodontia

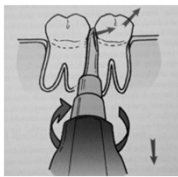
- ✓ Krekmanov, L. Swedish Dental Journal, 1974
- ✓ Ericsson, B. Swedish Dental Journal, 1984
- ✓ Hourigan, M. Exodontia Simplified, ADA Division of Communications Video, 1990
- ✓ Alonge, J. Tips from practicing dentists on using products to best advantage, ADA Dental Product Guide, 2014



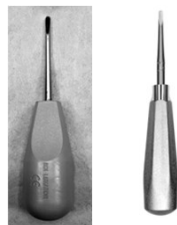Minimally Invasive Exodontia

Elevator

- 301
- 34S
- E303
- 77R
- 92R



*Luxator® EL3S

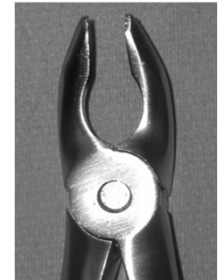


Minimally Invasive Exodontia

*Apical Retention Forceps

- Upper "universal"
- Lower "universal"
- Upper R/L Molar
- Lower Molar
- U/L Root Forceps

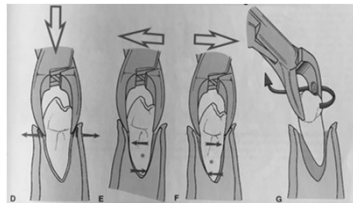
✓Karl Schumacher...A. Titan



"Forces of Exodontia"

- *Apical
- *Facial
*(Buccal/Labial)
- *Lingual/Palatal
- *Rotational
- *Traction

"It's all feel"



Principles of Exodontia

Axial Motion vs. Lateral Motion

1. Separation of sulcus connective tissues.
2. Luxation of Periodontal Attachment Apparatus ("PDL").
3. Application of rotational (torque) forces with forceps to the Periodontal Attachment Apparatus.

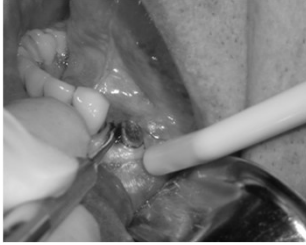
***SLOW** clockwise-counterclockwise...feel the resistance & hold.

*Steady pressure disrupts fibers...bone doesn't expand – it fractures.

*Special universal and anatomic universal forceps have excellent frictional values and are designed for positioning on solid tooth and root structure.

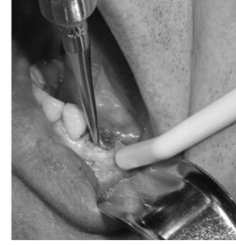Minimally Invasive Exodontia

Separation of Sulcus Connective Tissue



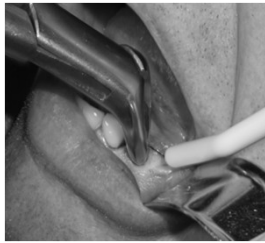
Minimally Invasive Exodontia

Luxation of Periodontal Attachment Apparatus

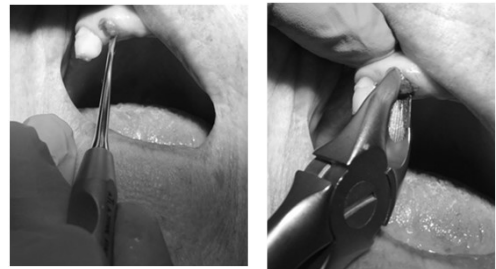

Minimally Invasive Exodontia

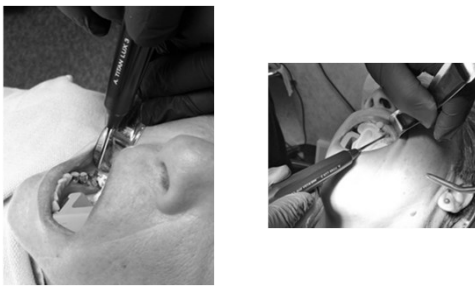
Application of Forceps



Minimally Invasive Exodontia

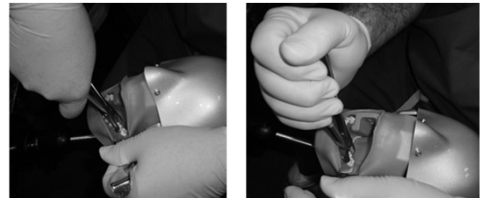


Minimally Invasive Exodontia

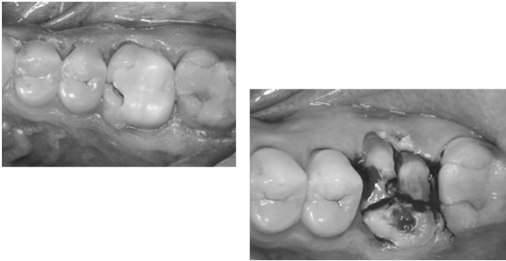


Minimally Invasive Exodontia

Forceps Technique



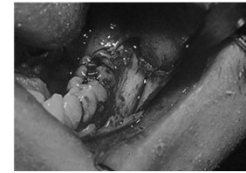
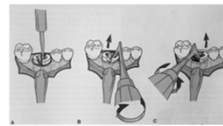Minimally Invasive Exodontia



Principles of Exodontia

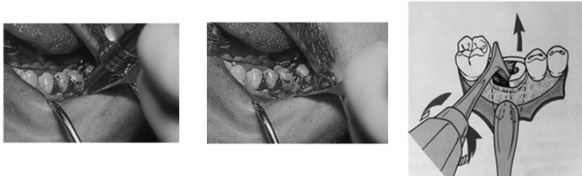Access

- *Principles of Flap Design
- Large enough to see
- Full thickness
- Margins on bone
- No tension with retraction
- Release one tooth away

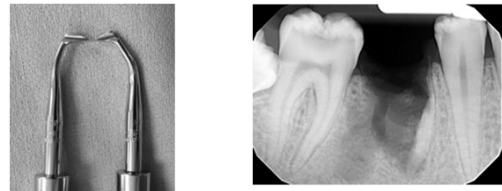


Principles of Exodontia

Pathways of removal

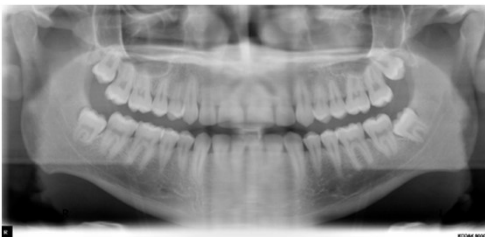

Minimally Invasive Exodontia



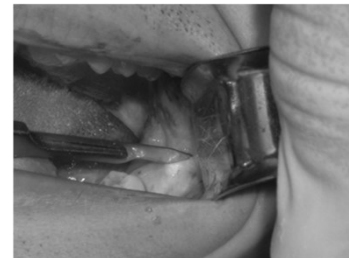3rd Molar Management

Techniques



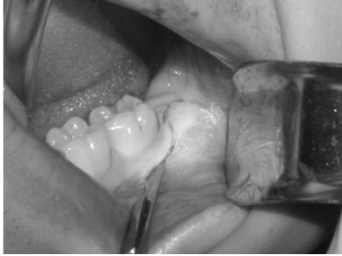3rd Molar Management

Mandibular Technique - Ext Oblique ridge to distal of 2nd molar

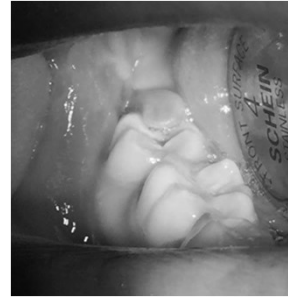

3rd Molar Management

Mandibular Technique – release just below mucogingival junction

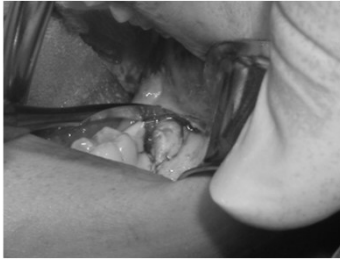


The operculum – excise as distal wedge



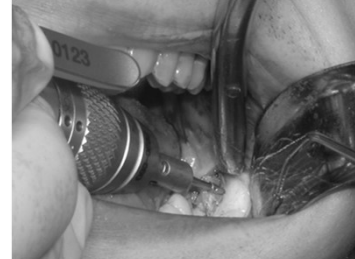3rd Molar Management

Mandibular Technique – reflect and retract



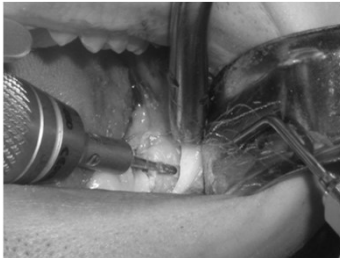3rd Molar Management

Mandibular Technique – buccal trough with 1703 bur



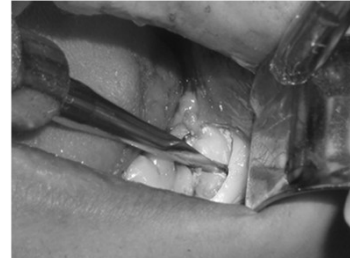
3rd Molar Management

Mandibular Technique - hemisection



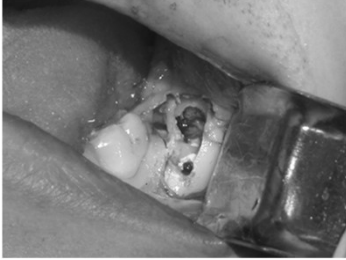3rd Molar Management

Mandibular Technique – complete split & remove distal root



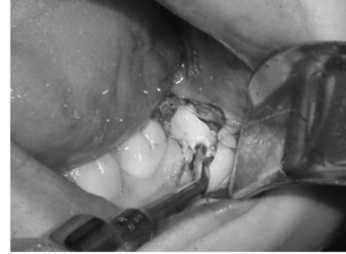3rd Molar Management

Mandibular Technique – make purchase point



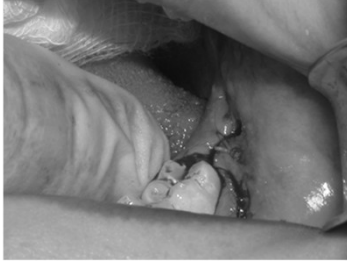3rd Molar Management

Mandibular Technique – remove mesial root with Cogswell B



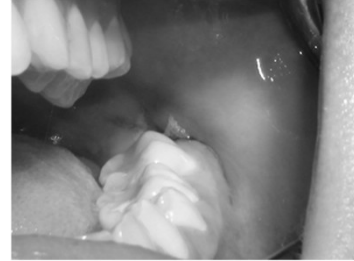3rd Molar Management

Mandibular Technique – one 3-0 plain gut suture



3rd Molar Management

Mandibular Technique – flap healing on POD #3



Mahalo nui loa!

jladoc@aol.com

